CHANGES TO THE AGING KIDNEY:

We have characterized several important changes to the kidney with advanced age. The following manuscripts on kidney aging were recently published from our lab:

(1) Changes in glomerular parietal epithelial cells in mouse kidneys with advanced age.
Roeder SS, Stefanska A, Eng DG, Kaverina N, Sunseri MW, McNicholas BA, Rabinovitch P, Engel FB, Daniel C, Amann K, Lichtnekert J, Pippin JW, Shankland SJ.
Am J Physiol Renal Physiol. 2015 Jul 15;309(2):F164-78. doi: 10.1152/ajprenal.00144.2015. Epub 2015 May 27.
PMID: 26017974

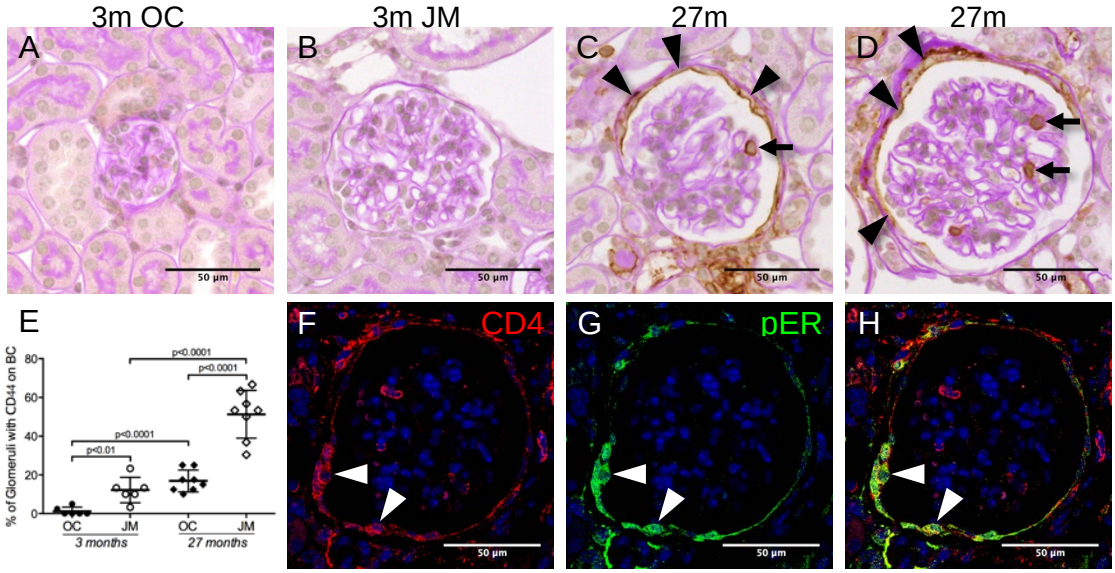

CD44 immunostaining increases in aged parietal epithelial cells, and co-localizes with phospho-ERK. (**A-D**) CD44 staining (brown, cytoplasmic) and PAS counterstain were performed in 3 month- (3m) and 27 month- (27m) old mice. Representative pictures were taken under the same magnification (400x); scale bars are provided. (**A**) CD44 staining was not detected in young mice aged 3m in the outer cortex (OC), (**B**) nor in the juxta-medulla (JM). (**C**) In contrast, in mice aged 27 m considered advanced age, CD44 staining was detected in cells lining Bowman's capsule in the OC (arrowheads). An occasional CD44 positive cell was detected in the capillary loops (arrow). (**D**) CD44 staining was readily detected in cells lining Bowman's capsule in the JM of 27m old mice (arrowheads). CD44 positive cells were detected in the capillary loops (arrows). (**E**) The percentage of glomeruli with CD44 stained cells on Bowman's capsule increases in 27 months old aged mice compared to 3 months old mice; the percentage was higher in JM glomeruli.
(**F-H**) Confocal microscopy images of immunofluorescent staining in JM aged glomeruli (400x magnification). Staining for (**F**) CD44 (red, white arrowheads show examples) and (**G**) pERK (green, white arrowheads show examples) are increased in cells lining Bowman's capsule. (**H**) CD44 and pERK co-localize (yellow color).

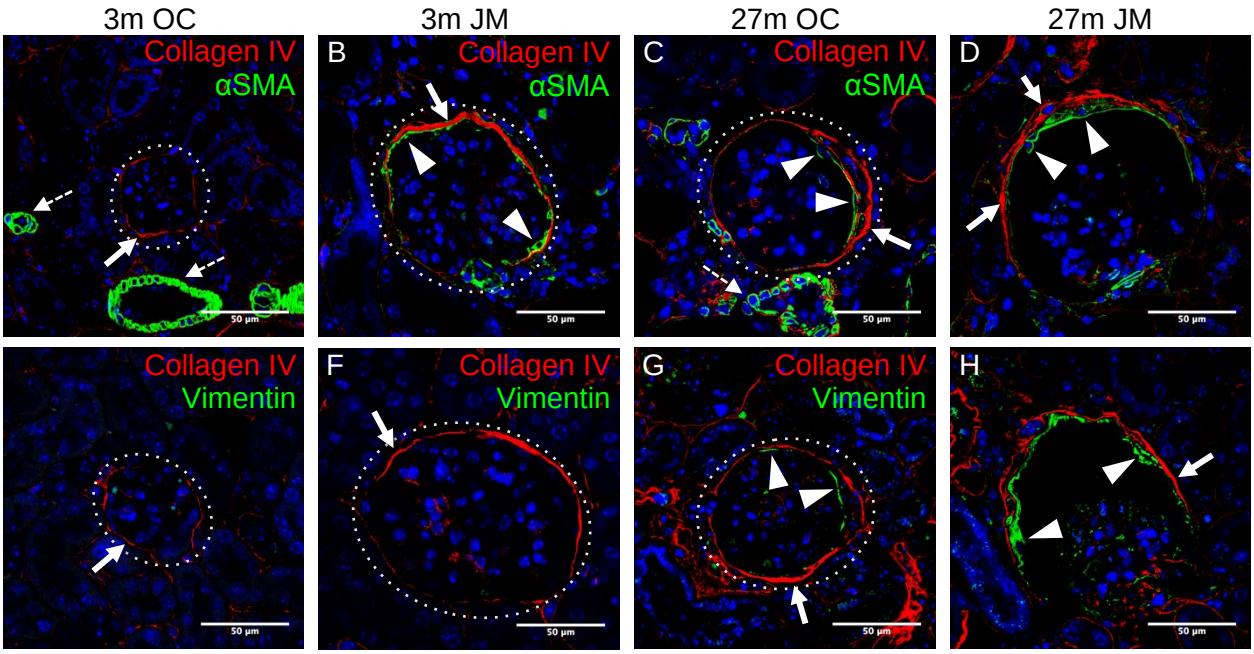

Immunostaining for the EMT markers alpha-smooth muscle actin (αSMA) and Vimentin increases in PECs in mice with advanced age.

(**A-D**) Confocal microscopy (400x magnification) showing immunofluorescent double staining for αSMA (green color, arrowheads) and collagen IV (red color, solid arrow) in young and old mice. Collagen IV staining was used to demarcate Bowman's capsule. Dashed circles indicate glomeruli. Scale bars are provided and nuclei stain blue with DAPI. (**A**) αSMA staining is not detected in outer cortical (OC) glomeruli of young mice aged 3 months (3m). The dashed arrows indicate positive staining in the adjacent vasculature, used as an internal positive control. (**B**) Light staining for αSMA is detected along the urinary side of Bowman's capsule (identified by collagen IV staining) in young juxta-medullary (JM) glomeruli. (**C**) In contrast to young mice, αSMA staining is readily detected in 27 month- (27m) old OC glomeruli. (**D**) αSMA staining is markedly increased in cells lining Bowman's capsule, consistent with PECs (arrowheads). When quantitated, the percentage of glomeruli with αSMA staining in cells lining Bowman's capsule (BC) is significantly higher in older OC and JM glomeruli.

(**E-H, I**) Confocal microscopy (400x magnification) showing immunofluorescent double staining for vimentin (green color, arrowheads) and collagen IV (red color, solid arrows) in young and old mice. Vimentin staining is not detected in PECs in young OC glomeruli (**E**) and only occasionally in young JM glomeruli (**F**). In old OC glomeruli, vimentin staining (arrowheads) was present in cells along Bowman's capsule (solid arrow)(**G**). In older JM glomeruli, vimentin staining was abundant along Bowman's capsule (**H**).

(2) Cells of renin lineage take on a podocyte phenotype in aging nephropathy.
Pippin JW, Glenn ST, Krofft RD, Rusiniak ME, Alpers CE, Hudkins K, Duffield JS, Gross KW, Shankland SJ.
Am J Physiol Renal Physiol. 2014 May 15;306(10):F1198-209. doi: 10.1152/ajprenal.00699.2013. Epub 2014 Mar 19.
PMID: 24647714

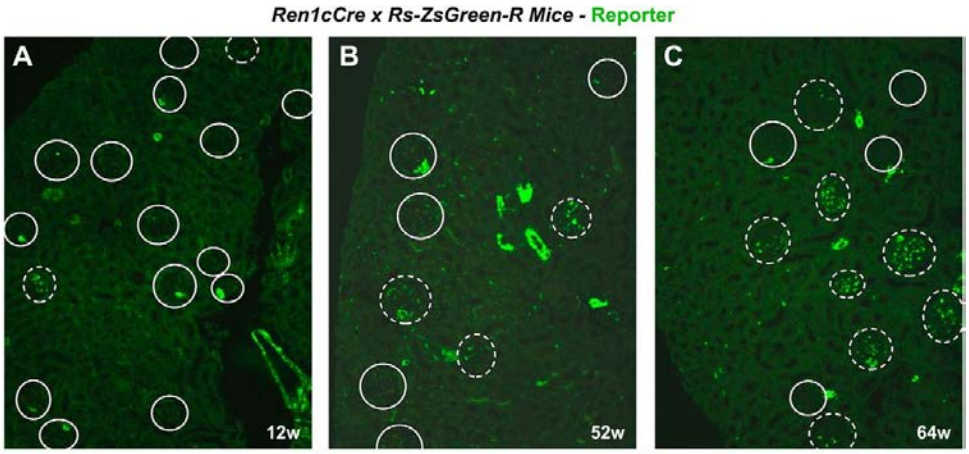

D

Weeks of Age	Percentage of glomeruli with reporter labeled CoRL	Percentage of glomeruli with injury	Percentage of glomeruli containing reporter labeled CoRL with injury	Percentage of glomeruli without reporter labeled CoRL with injury
12	27.67%	0.00%	0.00%	0.00%
52	29.35%	8.93% *	1.78% *	7.14% * §
64	38.87% * †	16.51% * †	4.14% * †	12.37% * † ‡

* P<0.05 vs. 12wks † P<0.05 vs. 52wks § P<0.05 vs. glomeruli containing labeled CoRL ‡ P<0.001 vs. glomeruli containing labeled CoRL

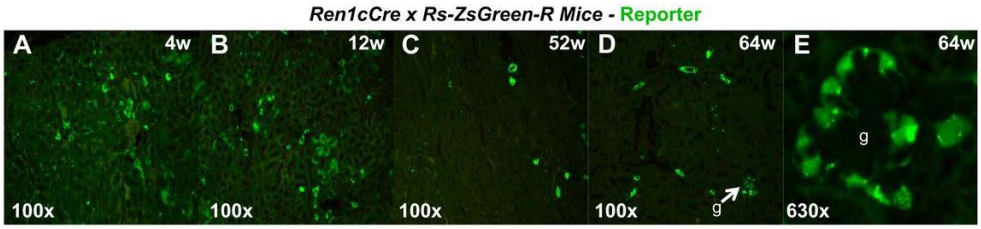

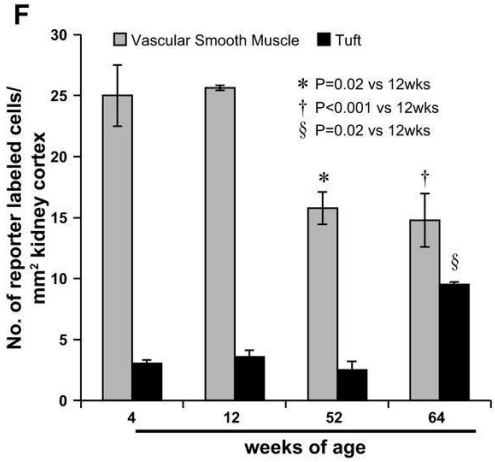

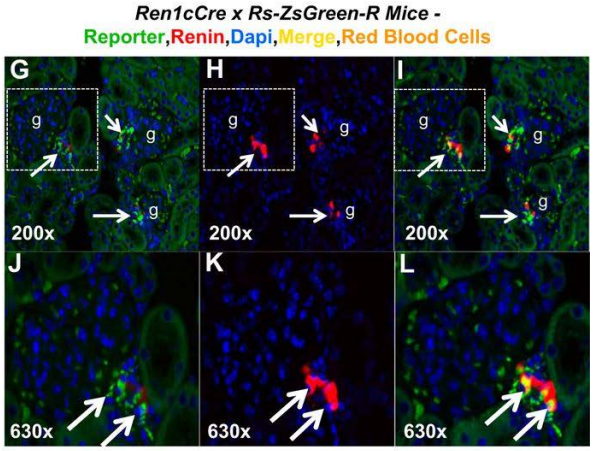

Labeled cells of renin lineage (CoRL) decrease in the extra-glomerular vascular smooth muscle compartment, and increase in the intra-glomerular compartment in aging nephropathy.

(A-E) shows representative pictures of kidneys from mice aged 4, 12, 52 and 64 weeks. (**A**) A low magnification image (100x) from a 4 week-old kidney shows that CoRL are permanently labeled with ZsGreen reporter in the extra-glomerular vascular smooth muscle compartment. They were rarely detected in the intra-glomerular compartment, and are faintly detected in the tubular compartment. (**B**) A low magnification image (100x) from a 12 week kidney shows a similar distribution of reporter labeled CoRL to 4 week kidneys shown in A. (**C**) At 52 weeks

reporter labeled CoRL decrease in the extra-glomerular vascular smooth muscle compartment. Labeled reporter cells were still rarely detected in glomeruli and in tubules. (**D**) At 64 weeks reporter labeled CoRL remained decreased in the extra-glomerular vascular smooth muscle compartment. However, there was a paradoxical increase in the number of reporter labeled CoRL in the intra-glomerular compartment (labeled g). (**E**) A glomerulus from a 64 week old kidney viewed at higher magnification (630x) shows a number of reporter labeled cells (green color) in the intra-glomerular compartment, which were in a characteristic podocyte distribution pattern.
(**F**) The number of ZsGreen reporter labeled CoRL was quantitated in *Ren1cCre* x *Rs-ZsGreen-R* reporter mice. Compared to 4 and 12weeks of age, the number of ZsGreen labeled cells decreased significantly in the extra-glomerular vascular smooth muscle compartment at 52 and 64weeks (gray bars). In contrast, there was an increase in the number of reporter labeled CoRL in the glomerular tuft (black bars) at 64weeks.
(**G-L**) *Representative images of double staining for renin and ZsGreen reporter*. (**G**) A lower magnification shows the distribution of CoRL reporter (green) was restricted to the extra-glomerular vascular smooth muscle compartment (arrows indicate examples). (**H**) The distribution of renin staining (red) was also restricted to the extra-glomerular vascular smooth muscle compartment (arrows indicate examples). (**I**) A merged image shows clear overlap of renin staining and the reporter (yellow, arrows indicate examples). Red blood cell autofluorescence appears orange in color. (**J-L**) higher magnification images of the glomerulus indicated by the white box in panels G-I respectively. These data show that renin staining is restricted to the extra-glomerular compartment, and that when labeled CoRL migrate to the glomerulus, they do not stain for renin.

(3) Interstitial pericytes decrease in aged mouse kidneys.
Stefanska A, Eng D, Kaverina N, Duffield JS, Pippin JW, Rabinovitch P, Shankland SJ.
Aging (Albany NY). 2015 Jun;7(6):370-82.
PMID: 26081073

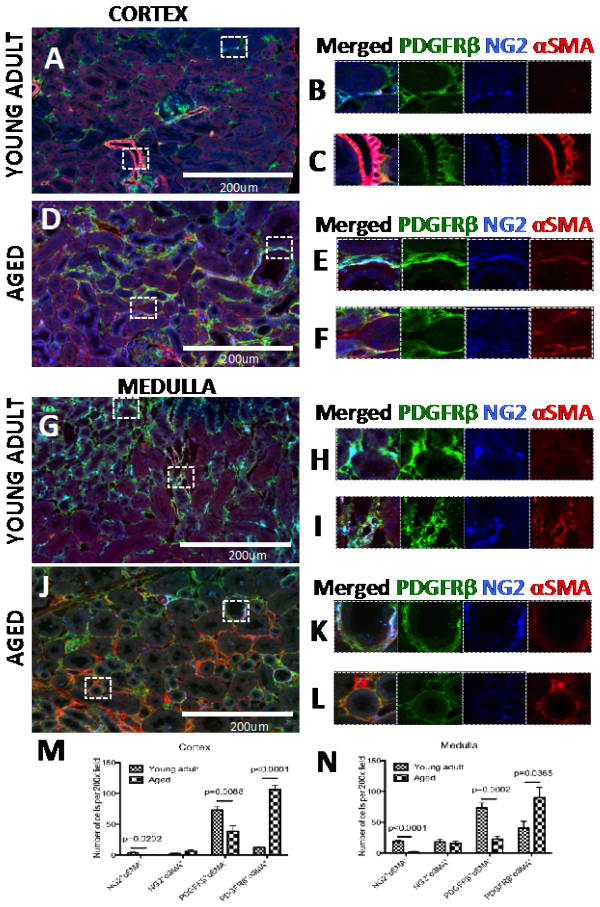

(4) De novo expression of podocyte proteins in parietal epithelial cells in experimental aging nephropathy.

Zhang J, Hansen KM, Pippin JW, Chang AM, Taniguchi Y, Krofft RD, Pickering SG, Liu ZH, Abrass CK, Shankland SJ.

Am J Physiol Renal Physiol. 2012 Mar 1;302(5):F571-80. doi: 10.1152/ajprenal.00516.2011. Epub 2011 Nov 30.

PMID: 22129965